

**University of Khartoum  
Faculty of Medicine  
Postgraduate Medical Studies**

**The Role of Sonographic Imaging in Acute Appendicitis in  
Khartoum Teaching Hospitals**

**By  
Dr. Jino David Ladu  
MB.Bs (University of Juba),  
MSc Human Morphology (U. of K)**

**A thesis submitted in partial fulfillment for the requirements of the degree of Clinical M.D.  
in Radiology  
January, 2005**

**Supervisor  
Professor Yahia Eltayeb Elarabi  
FRCS**

*DEDICATION*

*To my late brother William Andrug David  
who  
Succumbed in course of struggle*

## **ACKNOWLEDGEMENT**

I wish to acknowledge and thank Professor, Yahiya Eltayeb Elarabi in the Department of Surgery at University of Khartoum, whom I have consulted repeatedly regarding the preferable format of this thesis. He has been very much prudent in combing all the information giving suggestions, advice and encouragement.

I am also grateful to the co-supervisor Dr, Osman A/ Wahab, who kindly offered his mature expertise in ultrasound, to confirm the scanned cases.

I particularly wish to thank Dr Tariq Ali Yousif, Dr El Rayah Mustafa, Mr Daud Gideon Database consultant OCHA, Mr. Disseram Ephraim, Dr Agot Alier the Fedail Medical Center authority and lastly to my beloved wife Mrs Savia Aya for all the support and services she offered in preparation of this work.

## **List of Abbreviations**

AIDS	:Acquired Immunodeficiency Syndrome
AP	:Anteroposterior
CT	:Computerized Tomography
CRP	:C-Reactive protein
CMV	:Cytomegalo Virus
CXR	:Chest X-ray
E A	:Enlarged Appendix
EM	:Echogenic mucosa
GE	:Gastroenteritis
HA	:Hypochoic Appendix
LPE	:Loculated pericecal fluid
FIF	:Free intraperitoneal fluid
IPE	:Increased periappendiceal echogenicity
APP	:Appendicolith
MHz	:Mega Hertz
PID	:Pelvic inflammatory disease
PA	:Posteroanterior
P/R	:Per rectum
MMT	:Maximum mural thickness
RBCs	:Red blood cells
WBCs	:White blood cells
UTI	:Urinary tract infection
US	:Ultrasound
CME	: Continuous medical education
HIV	: Human Immunodeficiency virus
RIF	: Right Iliac fossa
N C	: Non -Compressible

## List of table

	<i>page</i>
Table 1, The site of primary pain -----	30
Table 2, The site of migratory pain-----	31
Table 3, The site of tenderness -----	32
Table 4, The leucocyte count -----	33
Table 5, Alvarado score of the patients -----	34
Table 6, The sonographic findings in the patients -----	35
Table 7, The position of the appendix -----	36
Table 8, Cross-tabulation of position on ultrasound and finding post-operative finding -----	37

## List of Figures

	<i>page</i>
Figure 1, Malrotated colon with various positions of the appendix-----	38
Figure 2, Retrocecal subhepatic appendix -----	39
Figure 3, Changing position of the appendix during pregnancy-----	40
Figure 4, The frequency of patients suspected of appendicitis according to age -----	41
Figure 5, Alvarado score within normal distribution curve- -----	42
Figure 6, Matching Alvarado score with ultrasound and Doppler findings-	43
Figure 7, Enlarged appendix with echogenic mucosa in longitudinal Scan-----	44
Figure 8, Enlarged hypoechoic appendix with appendicolith -----	45
Figure 9, Inflammed appendix with target sign in transverse scan-----	46
Figure10, Enlarged pelvic appendix crossing the pelvic brim with creeping fat sign -----	47
Figure11, Inflammed appendix with periappendiceal fluid collection- sealed perforation -----	48
Figure12, Enlarged appendix with breached mucosa and periappendiceal fluid collection -----	49
Figure13, Enlarged appendix with appendicolith in longitudinal scan-----	50
Figure14, Khartoum Teaching Hospital Emergency Department -----	51
Figure15, Consultation room of the Surgical Department -----	52
Figure16, The scanner used for the study-----	53

## **ABSTRACT**

### **Objectives:**

*To describe Sudanese experience in using ultrasound and Doppler ultrasound in diagnosis of acute appendicitis, incorporating Alvarado score.*

### **Materials and Method:**

#### **Design:**

*A randomized sample of patients suspected of acute appendicitis on clinical grounds, were scanned sonographically and the clinical findings were matched with Alvarado score.*

#### **Settings:**

*Patients were collected from Khartoum Teaching Hospital and Fedail Medical Center for scanning the patients.*

#### **Participants:**

*Sixty one patients (aged 7 – 60 years) seen in the surgical department suspected of appendicitis. Thirty-five males (57.4%) and 26 females (42.6%) all underwent ultrasonography.*

#### **Methods:**

*High frequency transducer was used, employing graded compression and Doppler technique.*

#### **Results**

*The typical inflamed, enlarged appendix with diameter of >6mm, and non-compressible was seen in most of the positive cases. Six patients (9.8%) had hypoechoic, fluid filled appendix. Five patients (8.2%) had loculated pericecal fluid collection. Three patients (4.9%) with echogenic mucosa and fluid filled appendix. Nine patients (14.5%) had appendicolith. Seven patients (11.3%) had creeping fat sign. One patient had free intraperitoneal fluid as complication of perforation. Of the forty three conditions of acute appendicitis, sonography was able to precisely determine the position of the appendix*

*twenty nine conditions (67.4%) being retrocecal in ten patients (23. %), pelvic in five patients(11.6%), preileal in two patients (4.8%), post ileal in four patients (9.3%), retrocecal subhepatic in two patients (4.8%)and paracecal in five patients (11.6%).On three conditions only, ultrasound has failed to determine the position of the appendix , it was only revealed by operative findings, and they were subcecal in position.*

*There was increased Doppler activity in 37 patients (86. %) with inflamed appendix.. Twenty-six patients (70.2%) were with score of 5 on Alvarado scale, followed by five patients (13.5% )with the score of 7,four patients (10.8%) with the score of 6,and two patients (5.4%)with the score of 4. Alvarado score, 4 , 5 , 6 lie under the normal distribution curve ,they represent the equivocal cases who could benefit from sonography, while the extremes 3 and 8 could either be for observation and operative management respectively. The sensitivity was 97% and specificity 100% in this study. The accuracy of Doppler ultrasound was 70.5%.*

### ***Conclusion:***

*This study has expressed a Sudanese experience in the sonographic imaging of acute appendicitis. It has confirmed the usefulness of ultrasonography as an additional diagnostic tool in appendicitis with high confidence.*

*Meticulous scanning, graded compression and Doppler ultrasound are invaluable adjunct tool in locating the position of the inflamed appendix, and for decision making in equivocal cases with Alvarado score,4,5,6.*



## خلاصة الاطروحة

### الاهداف:

تقيم الخبرة السودانية في استعمال الموجات الصوتية وموجات دوبلر Doppler الملون في تشخيص حالات التهاب الزائدة الدودية الحاد، مع دمج نظام نقاط الفرادو Alvarado Score.

### التصميم:

أخذت عينات عشوائية من مرضي يعتقد انهم مصابون بالتهاب الزائدة الدودية الحاد علي اساس العلامات السريرية. لقد اجري لجميع المرضي فحص الموجات الصوتية ليتلاءم مع العلامات السريرية ونظام نقاط الفرادو Alvarado Score

### الارتكاز:

مستشفى الخرطوم التعليمي كمركز يحول إليه الحالات و مركز فضيل الطبي لفحص موجات الصوتية.

### المشاركون:-

أحد وستون مريضا يتراوح أعمارهم ما بين 7 – 60 سنة تم تحويلهم إلي وحدة الجراح يعتقد انهم مصابون بالتهاب الزائدة. يوجد 35 ذكر (4و57%) و 26 انثي (6 و42%). تم الفحص عليهم جميعا بالموجات الصوتية. وجد 43 مريضا (5و70%) لديهم زائدة ملتتهبة ، 18 مريض (5و29%) حالاتهم للعلاج الطبي المحافظ.

تم تسجيل نقاط الفرادو Alvarado Score لجميع المرضي ، ونقاط تتراوح ما بين 2-8

## النتائج:

نموذج الزائدة الملتهبة تكبر وقطرها اكثر من 6 ملم ، وغير قابل للضغط وهكذا كانت الصورة في معظم الحالات الايجابية ، وجد 6 مرضي (8و9%) بالزائدة مليئة بسائل بدون اشارات صوتية. 5 مرضي (2و8%) لديهم سائل مسكني يحيط بأعوري . 3 مرضي (4و9%) ذو سائل وغشاء طلائي باشارات صوتية عالية. 9 مرضي (5و14%) لديهم تحصي الزائدة. 7 مرضي (3و11%) لديهم علامة الشحم الزاحف.

وجد مريض ذو سائل داخل التجويف الصفاقي 10 مرضي (23%) لديهم زائدة خلف الأعوري. 5 مرضي (6و11%) لديهم زائدة في الحوض، 5 مرضي (6و11%) لديهم زائدة جنب الأعوري ، 4 مرضي (3و9%) لديهم زائدة خلف اللفائفي، مريضين (4و8%) ، لديهم زائدة امام الفائفي ، و مريضين (4و8%) لديهم زائدة خلف الاعوري تحت الكبد.

في ثلاثة حالات تم التعرف علي موضع الزائدة ما بعد العملية وفي جميع الحالات كانت الزائدة جنب الأعوري .

لوحظ تزايد نشاط دوبلر Doppler Activity في 37مريض (6و60%) ذوي الزوائد الملتهبة . ستة وعشرون مريض (6و42%) كان لديهم خمسة نقاط الفرادو ، 5 مرضى (2و8) لديهم 7 نقاط الفرادو و 4 مرضى (6و6%) لديهم 6 نقاط الفرادو و، ومريضين (3و3%) لديهم 4 نقاط الفرادو .

تقع نقاط الفرادو 4,5,6 تحت منحنى التوزيع العادي وهي تمثل الحالات الغير قاطعة . ولذلك يمكنهم الاستفادة من التصوير بالموجات فوق الصوتية .

الحالات التي تقع في أقاصي المنحنى (أقل من أو يساوي 3) للعلاج المحافظ التقليدي، والعلاج بالتدخل الجراحي لنقاط (8 وما فوق) . الحساسية في هذه الدراسة كانت (97%) والتعيين (100%). ودقة الموجات الملونة 70.5% .

#### الاستنتاج:-

هذه الدراسة توضح التجربة السودانية في تصوير الزائدة الملتهبة بالموجات فوق الصوتية. أكدت مهمة الموجات فوق الصوتية كأداة إضافية في تشخيص حالات الزائدة الملتهبة بثقة عالية .

الفحص الموسوس والضغط المدرج والموجات الصوتية الملونة Doppler ادوات مساعدة لا يمكن التخلي عنها في التعرف علي موقع الزائدة الدودية ، واتخاذ القرار في الحالات الغير قاطعة بنقاط 4، 5، 6 علي نقاط الفرادو.

## **INTRODUCTION**

The role of ultrasound in the diagnosis of different causes of pathology is well-documented. It pinpoints to where other diagnostic procedures can judiciously be applied. Ultrasound is a non-invasive, low cost, safe and portable, this gives the practitioners easy access to this modality.

The characteristics of this modality make it advantageous for the developing world to have skilled people, who can maximize the limited power of purchase for getting good machines. Ultrasound has become firmly established as valuable means of diagnosis in many areas, and looked at as a natural extension of the clinical examination. Being a non-invasive means of imaging of the internal anatomy, and pathological changes that take place with resultant change in shape, size and structure of internal organs that can be detected. A wide range of processes affect these limited parameters.

The sonologist is required to demonstrate as many normal and abnormal findings, and to interpret them in the light of the clinical history, physical finding and other investigations. As sonography is operator-skill-dependent, skills of thorough examination, and knowledge of anatomy, pathology, medicine, surgery and other allied disciplines are required. Diagnostic accuracy in many areas remains high.

Bowel sonography is gaining grounds with the advent of high-resolution ultrasound machines, in conjunction with modified techniques. Since many years it is reported to be very sensitive in detecting air in abdominal cavity more than plain radiograms. Free abdominal fluid is easier to identify in Morrison's space, perisplenic space and the pelvis. Ultrasound can give general view of the viscera, not only can it show the intestinal wall with its inflammatory or neoplastic pathology, but also shows the surrounding tissues, useful for reaching correct diagnosis and therapeutic planning. Bowel gas, contained fecal matter and peristalsis need to be kept at the back of the mind while scanning to avoid misinterpretation, hence inaccurate reporting. Now it is possible to give accurate information in acute abdomen, rather than reporting about the complications. So it was recommended that extensive utilization of ultrasound examination in acute abdomen, of which acute appendicitis is the most common condition.<sup>1</sup>

## THE APPENDIX

It develops in the eighth week as protrusion from the terminal caecum, finally displaced medially by rapid caecal growth. Its base has constant relation with the caecum while the tip is either retrocaecal, pelvic subcaecal, preileal, postileal, paracaecal, these positions are important in clinical practice. Relative frequency of various anatomical positions of the appendix are, retrocaecal in 75%, pelvic in 21% and preileal, postileal, subcaecal and subhepatic constitute the remaining 5%.<sup>2</sup>

The subhepatic cecum and appendix, occurs if the cecum adheres to the inferior surface of the liver when returning to the abdomen. The liver draws the cecum

superiorly, and as the liver diminishes in size the cecum remains in its fetal position in the right hypochondrial region. This can also be seen in situs inversus. This condition is seen in about 6% of male fetuses. Inflamed appendix in this case will have referred pain to the right hypochondrial region.<sup>3</sup> See figure 1 (page 38) showing malrotation of the gut, where appendix lies in the left iliac fossa taking all possible positions. See figure 2 (page 39) showing retrocecal subhepatic appendix. The length of the appendix range from 1 –30cm average between 6 –9cm. Some cases of absence and duplication of the appendix were described. The appendix has an immunological role, in secreting IgA, and its removal has no predisposition to sepsis. Lymphoid tissues increase during puberty with a steady decrease with age, at 60 years no lymphoid tissue is found leading to complete obliteration of the lumen

### INFLAMMATION (APPENDICITIS)

Acute appendicitis, recognized as perityphilitis in 1500, but first appendectomy operation was in 1736. In 1889 Charles Mc Burney reported the importance of early operative intervention. Peak incidence at early adulthood with males affected more than females 1.3: 1. Eighty four percent of appendicectomies are for acute pathology, 16% for normal appendectomy in course of another operation mostly in females.

### ETIOLOGY AND PATHOLOGY

Luminal obstruction is a causative factor; it may be an appendicolith, less commonly by hypertrophy of the lymphoid tissue, inspissated faeces or barium

from previous contrast studies. Vegetables, fruit seeds and intestinal worms (ascaris) can also cause obstruction. Forty per cent of obstruction is caused by a faecolith that lead to acute appendicitis.

Sequelae of obstruction, closed loop obstruction leads to distension by the normal appendicular mucous secretion (normal 0.5ml) which leads to stimulation of visceral afferent pain fibers resulting in vague dull pain in mid abdomen /lower epigastrium.<sup>2</sup>

With progression of distension and the multiplication of resident bacteria leads to capillary and venous occlusion, which may cause nausea and vomiting with visceral pain becoming severe, and later peritoneal involvement occurs as then the pain shifts to the right lower quadrant. Progressive distension impairs the arteriolar pressure, especially in the antimesenteric border leading to infarction. Perforation is likely to occur with distension, bacterial invasion, and compromised perfusion. Some episodes of appendicitis subside spontaneously leaving thickening and scarring, suggesting old healed acute inflammation.

## BACTERIOLOGY

Varieties of bacteria, anaerobes, aerobes or facultative bacteria were cultured from peritoneal fluid, abscesses and appendicular tissues. Bacteroids fragilis and Escherichia coli were isolated from almost all specimens; other organisms are pepto-streptococcus 80%, Pseudomonas in 40%, Bacteroids splanchnus 40% and Lactobacillus 37%. CMV associated appendicitis has been reported in AIDS.

## CLINICAL FEATURES

These are discussed under three headings:

Group I, the common clinical features

Group II, the clinical features are according to location of the appendix and other factors.

Group III, the clinical features that differentiate between obstructive and non-obstructive acute appendicitis.

### GROUP I

- a. Symptoms, of pain around the umbilicus, due to distension of the appendix with moderate severity and cramps. Secondary pain located in RIF, which occurs in 1-12 hours, average 4-6 hours (i.e. parietal peritoneum irritation). Vomiting due to pylorospasm, only once or twice in 75%, if the stomach is empty then only nausea and no vomiting. Fever is usually 99-100 F (>37.3 C°), and constipation may be present.
- b. Physical signs, dry tongue, rapid pulse, tenderness and rigidity over RIF. Hyperaesthesia over Shevrens triangle with or without rebound tenderness, and Rovsing sign often positive, while bowel sounds may be absent<sup>2</sup>.

### GROUP II

- a. Anatomical location



- i. Retrocaecal appendix, irritation of the psoas muscle lead to spasm hence rights hip flexion.
  - ii. Pelvic appendix, P/R shows tenderness in the lateral wall plus suprapubic pain, and positive obturator internus sign (flexed and internally rotated hip cause pain). The patient can present with diarrhoea. Appendix in contact with the bladder may cause frequency of micturation.
  - iii. Subhepatic appendix seen with maldescended caecum causes tenderness in subhepatic region, and may mimic acute cholecystitis.
  - iv. Intraperitoneal (pre, postileal appendix), leads to irritation to ileum causing diarrhea, and localized or generalized peritonitis and collapse. Some times postileal appendix cause testicular pain and frequency of urine (i.e ureter and spermatic cord irritation).
- b. According to special factors: Age, obesity, pregnancy and HIV have their peculiar effect on presentation of acute appendicitis.
- i. Age, perforation, is seen earlier in young children, because of under developed omentum leading to peritonitis, diarrhoea also occur in this group. Children more than 8 years have two-fold increase in perforation. Gangrene and perforation occur much frequently in elderly patients with increased morbidity and mortality. Perforation occurs in 40% of patients at 80years of age.
  - ii. Obesity can obscure and diminish all the local signs of acute appendicitis.<sup>2</sup>

iii. In pregnancy, appendicitis is frequent extrauterine surgical disease in 1/200 pregnancies, mostly in the first two trimesters. The appendix is shifted up in the third month to the level of Mc Burneys point, at fifth months reaches the level of the umbilicus and at the eighth month is at the level of the transpyloric plane. Thus the increase in size of the uterus favors generalized peritonitis near term, even in patients without perforation there is greater the danger of peritonitis. Perforation is seen in more than half of the conditions, the mortality in late pregnancy is 5%. Fetal mortality increases from 3-5% with early appendicitis up to 20% with perforation.<sup>4</sup> Figure 3 (page 40) showing the position of the appendix during pregnancy.

iv. . AID/HIV patients, the course is as for general population, and opportunistic infections such as CMV and disease like Kaposi sarcoma which affect the gastrointestinal tract may be responsible for the development of appendiceal inflammation.<sup>2</sup>

### GROUP III

In the non-obstructive appendicitis the umbilical pain last less and merge into that of peritonitis, which is exacerbated with coughing and straining. While in obstructive appendicitis going on for gangrene and perforation, the colicky pain stays longer and it is profound with severe vomiting, high temperature and tachycardia. The clinical events occur quickly and early diagnosis and treatment is more urgently required.

## LABORATORY FINDING

Mild leucocytosis  $10,000-18,000\text{mm}^{-3}$  with moderate polymorphonuclear predominance, high counts increase the possibility of abscess, perforation and urine may have both RBCs and WBCs as result of irritation of the ureter or bladder.

## RADIOGRAM

Plain films may show abnormal gas pattern of dilated loops with or without or presence of faecolith. The presence of appendicolith is highly suggestive of the diagnosis. CXR rules out the presence of right lower lobe pneumonia where acute pain is referred to the abdomen.

## SONOGRAPHY

Graded compression is an accurate way to diagnose appendicitis, which is seen as a blind ending non-peristaltic bowel loop originating from the caecum. Inflamed appendix is non-compressible and the cross sectional diameter is more than 6mm. Appendicolith establishes the diagnosis by posterior casting shadow. The whole of the abdomen is surveyed to exclude possible causes of acute abdomen.

Sonographic diagnosis of acute appendicitis has sensitivity of (78%-96%) and specificity of (85% -98%) it is less sensitive in children and pregnant women. CT is more accurate but is expensive, hence it is reserved for appendicular abscesses. Non-filling of the appendix in barium study carries the accuracy of 50%-84%, however it is contraindicated in acute abdomen.

## DIFFERENTIAL DIAGNOSIS

Erroneous preoperative diagnosis could be as much as 75% of acute abdomen, it includes acute mesenteric lymphadenitis, acute PID ,twisted ovarian cyst, rupture Graafian follicle, acute GE, Meckel's diverticulitis, Intussusception in less than two years and perforated peptic ulcer.

Sonography could be useful in sorting out some of the pathology especially in the pelvis such as ruptured ectopic pregnancy

## TREATMENT

After the diagnosis, the patient should be prepared for operative (open surgery), laproscopic surgery, or conservative treatment.

## PROGNOSIS

The mortality rate in USA was 9.9% in 10,000 in 1939.It fell to 0.2% in 100,000 in 1986, this is due to better awareness, early diagnosis and treatment .The principle factors in the high mortality are, rupture before surgical treatment and the age of the patient, very young and old patients.

Death is attributed usually to sepsis i.e peritonitis, intrabdominal abscess pulmonary embolism, and aspiration.

## MORBIDITY

Morbidity is increased by rupture of the appendix in old age, wound infection, which has been reduced by use of metronidazole .Abscess collection frequently is seen in pouch of Douglas, the subhepatic space, and between the loops of intestine.

Sloughing of part of the caecum and slipping of purse string suture may cause fistula. Late complications are quite uncommon.<sup>2</sup>

## **LITERATURE REVIEW**

Standards and guidelines were set to provide assistance to practitioners performing ultrasound studies of the abdomen or retroperitoneum. Depending on the clinical examination it may include the abdomen, retroperitoneum or single organ, in some cases specialized examination (color Doppler, spectral or power Doppler). There are many indications for ultrasound examination, these include abdomen, flanks /back pain, palpable masses, organomegaly and abdominal trauma. Abdominal or retroperitoneal ultrasound should be performed when there is a valid medical reason. There is no absolute contraindication .The bowel can be evaluated for wall thickness (maximum mural thickness MMT), dilatation (increase in AP diameter), muscular hypertrophy, masses and other abnormalities. Graded compression, is a technique of steady compression that is necessary to visualize the appendix or other bowel loops. It is combined with pelvic sonography in the evaluation of pelvic pain. <sup>5</sup>The accuracy of both clinical impression and ultrasound examination in detecting the cause of peritonitis was compared. Ultrasound and clinical

impression accurately diagnosed the cause of peritonitis in 85 (83%) and 52 (51%) of patients respectively. Emergency ultrasound study needs a particular expertise because one must solve quickly the differential diagnoses in unprepared patients. Paralytic ileus is the most important cause of artifact obscuring ultrasound examination; the diagnostic confidence of ultrasound allows the recognition of the most typical pattern of neoplastic and inflammatory pathology of gastrointestinal tract. Normal appendix is usually very badly detectable and land markers to identify the appendix are the iliofemoral vessels, iliac crest, psoas, parietal peritoneum, caecum and terminal ileum. The classical appearance of inflamed appendix is concentrically layered structure in transverse section showing target sign. Free fluid or abscess collection can also be observed close to the appendix, wall thickness of the terminal ileum due to inflammatory reaction could also be observed. Extensive utilization of ultrasound is recommended in urgent examination of acute abdomen. <sup>6</sup> Three hundred patients suspected to have appendicitis were studied using non-enhanced helical CT. The study concluded that non-enhanced CT is a highly accurate technique for diagnosing or excluding acute appendicitis.<sup>7</sup> The role of helical CT in differentiating acute appendicitis and acute gynecological conditions was studied and the conclusion is that helical CT is an excellent imaging option for differentiation.<sup>8</sup> CT was found to be beneficial for evaluating patient with suspected recurrent or chronic appendicitis.<sup>9</sup> The role of un-enhanced CT in management of acute flank pain was evaluated and found to be accurate in establishing the cause of the pain.<sup>10</sup> Evaluation of MR

imaging and sonography were correlated, and the conclusion was that the MR imaging is superior to sonography in revealing suspected acute appendicitis. MR imaging can be used after suboptimal or non-diagnostic sonography in patients of suspected acute appendicitis.<sup>11</sup> Evaluation of the use of sonography in diagnosing acute appendicitis in a teaching hospital and community hospital concluded that there is no significant difference between teaching, and non-teaching hospitals in the frequency of use of sonography in diagnosing patients with appendicitis.<sup>12</sup>

Computed tomography and ultrasound correlation in acute appendicitis in 100 patients was conducted and the conclusion was that CT is more accurate than ultrasound in diagnosis of acute appendicitis.<sup>13</sup> A critical appraisal of the value of immediate ultrasound in acute abdominal conditions led to the establishment of the diagnosis and shortening the duration of in-patient care.<sup>14</sup> Graded compression ultrasonography is an examination of choice if there is doubt whether an appendectomy is to be performed.<sup>15</sup> Ultrasound with graded compression is useful in evaluation of acute appendicitis in concordance with the reports in literature.<sup>16</sup>

Using Doppler ultrasound, no activity will be detected in the wall of normal appendix; while with an inflamed appendix there will be increased activity within the wall.<sup>17</sup> Evaluating graded compression ultrasonography in differential diagnosis of appendicitis; the predominant role of ultrasound in evaluating appendicitis is not as independent diagnostic determinant. Instead it is most useful as a mean of improving decision making when considered in combination with

thorough history and physical examination in those patients who present diagnostic dilemmas.<sup>18</sup> Sonography, with the clinical finding were compared and the conclusion was that clinical judgment and ultrasound were statistically highly significant as predictors of acute appendicitis, where as the indications given by C-reactive protein and WBCs count did not reach statistical significance.<sup>19</sup>

Ultrasound examination of adolescent females with lower abdominal pain concluded that, pelvic ultrasound examination might be a useful diagnostic adjunct in these patients.<sup>20</sup> Intestinal ultrasound seems important as a first diagnostic tool in young patients without clear symptoms or signs as an indicator that subsequent tests are required. Normal appendix can be visualized in a high percentage with diameter of 6mm as upper limit of normal. A significant percentage of appendicitis resolve spontaneously, especially when confined to the tip. In retrocaecal appendix seen posterior to the caecum the inflammation originates at the tip and the base is smaller in A P diameter than the distal appendix .<sup>21</sup> Alvarado score for the diagnosis of acute appendicitis, is a system of ten scores based on symptoms, signs and clinical tests. Using this system negative appendectomy rate is less than 15%, perforation rate less than 35%, missed perforation less than 15% and missed appendicitis less than 5%. Comparing ultrasound and Alvarado score system in the evaluation of suspected patients of acute appendicitis, neither one is significantly advantageous, false positive rates decrease to zero when both studied are positive, and ultrasound improves the diagnostic accuracy when Alvarado score is negative or equivocal.<sup>22</sup> Using modified Alvarado score, higher scores were



found to perform poorly in predicting the diagnosis of acute appendicitis pre-operatively and in reducing negative appendectomy. Incorporating Alvarado score has no advantage over clinical suspicion.<sup>23</sup> Alvarado score is a useful tool in the diagnosis of appendicitis, especially at both ends of the scale. Forty-six patients with Alvarado score of 1-4 were scanned and none of them had sonographic signs suggesting appendicitis. Out of forty patients having Alvarado score 5-6 only 2 patients had sonographic sign of appendicitis, while 30 patients out of 44 with Alvarado score of 7-8 had positive sonographic signs of appendicitis. Eighteen patients with score of 9-10 all had sonographic signs of acute appendicitis. The diagnostic yield is higher with high scores, while the reverse is true for lower scores.<sup>24</sup> Evaluation of modified Alvarado score, high score was found to be a dependable aid both in preoperative diagnosis of acute appendicitis and the reduction of negative appendectomies in men and children, but the same was not true for women who had high false positive rates for acute appendicitis.<sup>25</sup>

Clinical assessment in diagnosing appendicitis by experienced surgeon remains reliable and superior to both Alvarado score and CRP measurement. Nevertheless Alvarado score and serum CRP may be of value in the inexperienced surgeon and a high Alvarado score and serum CRP should not be ignored.<sup>26</sup> Studying negative appendectomies and perforation rates, women suspected of appendicitis benefit most from pre-operative CT or ultrasound with a statistically significant lower rate of negative appendectomies rate than women who under go no preoperative

imaging. It is therefore, considered that preoperative imaging is important in suspected appendicitis in women.<sup>27</sup>

Graded compression has helped in the diagnosis of acute appendicitis<sup>28</sup>

In the evaluation of 6mm criterion, it was found to be of high sensitivity.<sup>29</sup> The appendiceal mural thickness for children is usually less than 3mm.<sup>30</sup> Concerning the evaluation of gas in the inflamed appendix, it was found to be a reliable sign to exclude appendicitis.<sup>31</sup> Ultrasound is recommended in doubtful conditions of appendicitis in children<sup>32</sup>

There was a case report of appendicitis in a nine- month child with a classical feature<sup>33</sup>. Despite the fact that Alvarado score is safer, faster and accurate, it fails to provide better results without clinical diagnosis<sup>34</sup>.

Plain abdominal films are frequently misleading in appendicitis<sup>35</sup>. A comparison was done between ultrasound and CT for children on clinical suspicion of appendicitis; perforation rates were not significantly different<sup>36</sup>. The sensitivity, specificity and the predictive value for Doppler were 86%, 96%, and 72% respectively<sup>37</sup>. Imaging has lead to earlier diagnosis of appendicitis and hence lower morbidity and mortality rates<sup>38</sup>.

## **OBJECTIVES**

1. To describe the first Sudanese experience in sonographic imaging of acute appendicitis
2. To determine the accuracy of Doppler ultrasound in picking the hyperaemia of acute appendicitis

- 
- 
3. To correlate the sonographic Doppler finding with the Alvarado score for diagnosis of acute appendicitis

## **PATIENTS AND METHODS**

This study is targeting patients who present to Khartoum Teaching hospital surgical department, and after consultation were suspected of having acute appendicitis.

The study population consisted of 61 patients aged between 7-60years, males (M= 35, 57.4%), females (F= 26, 42.6%) with a male: female ratio of 1.34:1 who were sent for ultrasound evaluation, on clinical suspicion of acute appendicitis. The patients were scanned, and later the diagnoses were confirmed by two senior sonologist having expertise in bowel scanning.

The ultrasound machine used was from Shimadzu company -SDU-2200 – Diagnostic US system, with 2-5/2-5.5and 5-10MHz curved and linear probes. Doppler facilities (color and power), image storage was done by magneto-optic disc (MOD). Attached accessories are printers (thermal paper and colored printer), the appliance uses 220-240 volts .Gel, Aquasonic US gel by Parkers laboratories (USA).

### **PROBE MANIPULATION TECHNIQUE**

Recognition of the transducer orientation was the most important factor to begin with. The position where the index appeared is kept towards patients head for sagittal sections, and towards the right of the patient for transverse section .The probe (i.e. linear 7-10MHz) was held with the operators fingers close to the transducer face and with the little finger rest on the patient skin, so that the

maximum control is exerted in this way the transducer will not slide off the scan plane, and is kept steady on the patients skin, at the correct angle.

## SCANNING TECHNIQUE

### 1 Work Station

Operator comfort was observed, and that the forearm and the hand are gently resting on the patient, with the spine erect and the eyes at the level of the system monitor. Most of the scans were taken with the operator seated, on few occasions standing to maximize visualization. No patient on trolley was scanned. Ultrasound gel (Aquasonic) in sufficient amount is applied over the proposed scan area. Application of insufficient gel was avoided as it makes poor contact with skin surface, hence reducing the mobility of the transducer face over the skin.

### 2. Scanning

Always a swift survey scan of the abdomen is done before focusing onto the right iliac fossa. This enables the operator to understand the anatomy under view.

Three approaches were used for viewing the inflamed appendix :

- a. Starting by the area of maximum tenderness
- b. Starting from a point 2cm to the right of the umbilicus and moving further lateral to reach the ascending colon following it to the caecum then searching for the appendix.
- c. Posterolateral approach mainly employed for viewing retrocaecal subhepatic appendices.

### 3. Tranducer movement

Smooth freely flowing transducer movement is kept in all the examinations, allowing proper time for the operator to view the real time image in the monitor without constant checking the transducer position. When the area of interest has been reviewed the transducer movement is slowed, and small amount movements in one plane at a time, to avoid confusion and lose sight of the appendix. Transducer movements are, rotation, angling, tipping, and moving up and down and side to side (glidding)

### 4. Graded compression

- a. Graded compression, is a maneuver that was employed concurrently with transducer movement. This procedure involves application of firm pressure on the transducer, which significantly improves the imaging of deep structures. It decreases the distance between transducer and the target, allowing the use of higher frequency probe, the displacement of gas filled colon improves skin /probe contact and minimizes artifacts.

Gradual graded compression was used since this is well tolerated by most patients even those who are experiencing significant pain. A non-compressible appendix indicate distension commonly seen with inflammation, compression could be a failure in case the inflammation is at the tip of the appendix, gangrenous or perforated appendix. The technique is used in diagnosing appendicitis as well as

significant disease processes, which may clinically mimic appendicitis, e.g. ileocolitis

#### 5. Multiple scan planes

The appendix was viewed in at least two different planes (orthogonal) longitudinal and transverse sections being the minimum. This easily resolves the confusion concerning the nature of structure e.g. appendix, epiploic appendices. Survey of the entire length of the appendix should be performed, to avoid a false negative examination, when inflammation is confined to the tip of the appendix. A full urinary bladder in females impedes examination of the appendiceal region, hence half empty bladder is preferable. Seen in transverse plane, alternating echogenic and hypoechoic concentric layers should be sought, corresponding to the various layers of the bowel wall, normally five distinct layers. A positive examination consists of identifying an abnormally inflamed appendix as turgid thickened with diameter of  $> 6\text{mm}$  with fluid in the lumen. There could be free fluid too. The appendix fails to compress or part of it fails to be compressed.

#### 6 Pitfalls in diagnosis:

The normal appendix may be mistaken for an inflamed one. Normal features include compressibility, absence of Doppler signal and inflamed fat (creeping fat sign). False positive results are seen in case of thickening of the appendix associated with perforated peptic ulcer, Crohn's disease, caecal carcinoma or perforating sigmoid disease. Most important reason for false negative examination is overlooking the inflamed appendix. Generalized peritonitis hampers graded



compression; air filled dilated loops and ileus obscure the appendix. Thickening of the ileal walls also cause confusion. In advanced conditions with peritonitis, appendicitis only shows reflective non-compressible inflamed fat of the omentum, and mesentery is visualized and inflamed appendix is overlooked, thus this may lead to erroneous diagnosis of omental infarction or epiploic appendigitis.

Colour Doppler sonography was used as adjunct to gray scale sonography for improving observer confidence in diagnosis of appendicitis. Colour Doppler should be used in conjunction with gray scale ultrasound in the evaluation of acute appendicitis, and with initial appendiceal inflammation there may be no detectable increase in Doppler flow signal. Decision matrix was used to calculate sensitivity, specificity, accuracy, positive and negative predictive values using these formulae.

#### Formulae for statistical tests

Accuracy = number of correct tests/total number of tests

Specificity = number of correct negative tests/number without disease

Sensitivity = number of correct positive tests /number with disease

Positive predictive value = number of correct positive tests/number of positive tests

Negative predictive value = number of correct negative tests /number of negative tests.

Figures 14,15,and 16 show the facilities used in the study in page 49-52.

## **RESULTS**

Ultrasound scan was performed in 61 patients with the clinical diagnosis of acute appendicitis. There were 35 males (57.4%) and 26 females (42.6%) with a male to female ratio of 1.34:1 and age range of 7 years to 60 years. Twenty- eight patients (45.9%) reported with primary pain in the umbilical region. Eighteen patients (29.5%) had epigastric pain, 4 patients (6.6%) had vague abdominal pain. One patient (1.6%) had generalized abdominal pain, another one had pain in the flank, and 9 patients (14.8%) had no primary pain. Table 1(page 30) shows the frequency and percentage according to the site of primary pain.

Migratory pain to the RIF was present in 40 patients (65.6%). In 7 patients (11.5%) the pain migrated to the flank, and in 4 patients (6.6%) to the suprapubic region, in one patient (1.6%) the pain migrating to right hypochondrial region, and in another patient, the pain migrated to the right testis. Eight patients (13.1%) had no migratory pain. Nausea and vomiting was present in fifty-four patients (88.5%) while 7 patients (11.5%) did not have it. Table 2(page 31) shows the frequency and percentage according to the site of the migratory pain. Tenderness of the RIF was present in 46 patients (75.4%), tenderness of the flank was present in 7 patients (11.5%). One patient (1.6%) had tenderness in the right hypochondrial region. Two patients (3.3%) had tenderness on P/R examination. One patient (1.6%) had suprapubic tenderness and another presented with appendicular mass. There was no tenderness in 3 patients (4.9%). Table 3 (page 32) shows the frequency, percentage and the site of tenderness. Although rebound pain was elicited in 56 patients (91.8%), it was negative in 5 patients (8.2%). The body temperature was raised above (i.e.>37.3 C<sup>o</sup>) in 8 patients (13.1%) while it was normal in the remaining patients. Although the majority of patients 48(78%) had white count within the normal range, the leucocyte count was found above 10000/mm<sup>-3</sup> in 13 patients reaching a maximum of 15900/mm<sup>-3</sup> (21.3%). Table 4(page 33) shows the frequency and percentage of the leucocyte count.

Four patients (6.6%) had CXR PA view all of which were normal; one patient had a plain abdominal film, which was also normal.

Alvarado scoring system was used for patients with a score ranging between 2 and 8 suspected of acute appendicitis. There were only two and three patients with the second and the third score respectively. The peak frequency occurred at 4 and 5 scores being 16 patients (26.2%) and 28 patients (45.9%) respectively. The frequency fell gradually on the ascent of the scoring system to 8. There were 5 patients in 6 and 7 scores, it then fell sharply to two in the 8<sup>th</sup> score. Table 5 (page 34) shows the frequency and percentage of patients scatter according to Alvarado score.

Fifteen patients (24.5%) with appendicitis were seen within the age range of 20-24 years, followed by ten adolescent patients (16.3%) at the range of 15-19 years of age. Few patients were seen at the extremes. See figure 4 (page 41) showing the frequency distribution of patient according to age. Sonographic finding consisted of constellation of many ultrasound signs that occurred in and around the appendix. Table 6 (page 35) shows sonographic findings of a total of 61 patients with suspected appendicitis. Eighteen (29.5%) had negative ultrasound finding, and in nearly half of these patients the appendix was seen and considered normal sonographically so an alternative diagnosis was suggested. Forty three patients (70.5%) showed evidence of inflammation of the appendix. The table groups the patients according to presence of similar ultrasound finding which in all make the diagnosis of appendicitis. Six patients (14%) had enlarged appendices, hypoechoic, fluid filled, and non-compressible. Four patients (9.2%) had enlarged appendices which are hypoechoic, with loculated pericaecal fluid, and non-compressible. Three

patients (7%) had enlarged appendices, which had echogenic mucosa fluid filled, non-compressible. Two patients (4.7%) had enlarged, hypoechoic appendices which were non-compressible with appendicolith. Two patients (4.7%) had enlarged appendices, which were fluid filled with increased periappendiceal echogenicity, and were non-compressible. Two patients (4.7%) had enlarged appendices which were, hypoechoic, with echogenic mucosa, and were non-compressible. Two patients (4.7%) have enlarged hypoechoic appendix with echogenic mucosa, fluid filled and non-compressible. Seven patients (16.3%) had appendicolith. One patient (2.3%) had loculated pericaecal fluid (i.e. sealed perforation). Five patients (11.6%) had increased periappendiceal echogenicity (i.e. creeping fat sign). One patient (2.3%) had free intraperitoneal fluid (i.e. perforation as complication). In 29 patients the status of the inflamed appendices were, 26 with acute mural appendicitis, one gangrenous, one perforated and one with appendiceal mass. The position of the appendix included 5 pelvic, 5 paracaecal, 10 retrocecal and there was a female with right ovarian cyst, 2 preileal, 2 retrocecal and subhepatic, 4 postileal, one with adhesion to the ileum. See table 7 (page 36) for the position of the appendix. However in 3 patients ultrasound failed to reveal the position of the appendix. In the postoperative findings, these were found to be subcecal appendices, of which two were perforated and one just inflamed appendix.

In eleven conditions neither ultrasound nor surgery could add information about the position of the appendix due to lack of operative response. Table 89(page 37) is showing the position of the appendix and operative finding in cross-tabulation.

Thirty-seven patients (86%) out of the forty-three had increased Doppler activity in the inflamed appendices. Twenty-six patients (42.6%) were with the score of 5, two patients (3.3%) with the score of 4. Five patients (8.2 %) with the score of 7 and four patients with the score of 6. The range of scores 3-7 and 3-8 scores was tested statistically with superimposition of the normal distribution curve, and coefficient of variation of 19.9% was nearer to the normal distribution, and this was for the range of 3-7 scores. Scores of 4, 5, 6 lie under the curve while 3 and 7 scores lie at the extremes see figure 5 showing Alvarado score within the normal distribution curve (page 41). Eighty six percent of patients with acute appendicitis had Doppler activity with the accuracy of 70.5%. Figure 6(page 43) is showing matching of ultrasound and Doppler findings. The calculated sensitivity and specificity in this study is 97%and 100% respectively.

Table 1: The site of Primary Pain

<b>Pain site</b>	<b>Frequency</b>	<b>Percent</b>
Umbilical	28	45.9
Epigastric	18	29.5
Vague	4	6.6
Generalized	1	1.6
Flank	1	1.6
No primary pain	9	14.8
<b>Total</b>	<b>61</b>	<b>100.0</b>

Table 2: Migratory Pain

<b>Pain site</b>	<b>Frequency</b>	<b>Percent</b>
RIF	40	65.6
Flank	7	11.5
Suprapubic	4	6.6
Right hypochondriac	1	1.6
Testicular	1	1.6
No migratory pain	8	13.1
<b>Total</b>	<b>61</b>	<b>100.0</b>



Table 3: The site Tenderness

<b>Site of tenderness</b>	<b>Frequency</b>	<b>Percent</b>
RIF	46	75.4
Flank	7	11.5
Right hypochondriac	1	1.6
On P/R	2	3.3
RIF with a mass	1	1.6
Suprapubic	1	1.6
No tenderness	3	4.9
<b>Total</b>	<b>61</b>	<b>100.0</b>

Table 4: The Leucocyte Count

<b>Count</b>	<b>Frequency</b>	<b>Percent</b>
Normal count	48	78.7
10000 <sup>-3</sup>	3	4.9
11000 <sup>-3</sup>	1	1.6
12000 <sup>-3</sup>	2	3.3
12500 <sup>-3</sup>	1	1.6
13400 <sup>-3</sup>	1	1.6
14000 <sup>-3</sup>	1	1.6
14100 <sup>-3</sup>	1	1.6
15000 <sup>-3</sup>	2	3.3
15900 <sup>-3</sup>	1	1.6
<b>Total</b>	<b>61</b>	<b>100.0</b>

Table 5: Alvarado Scores of the patients

<b>Score</b>	<b>Frequency</b>	<b>Percent</b>
2	2	3.3
3	3	4.9
4	16	26.2
5	28	45.9
6	5	8.2
7	5	8.2
8	2	3.3
<b>Total</b>	<b>61</b>	<b>100.0</b>

Table 6: The Sonographic Findings

<b>Findings</b>	<b>Frequency</b>	<b>Percent</b>
LPF/IP	1	1.6
EA/APP	1	1.6
EA/ Partially compressible	1	1.6
AP/HA/NC	2	3.3
EA/AC/NC	1	1.6
EA/FFA/NC	1	1.6
EA/EM/FFA/Partially compressible	1	1.6
HA/LPF/IPE	1	1.6
EA/HA/FFA/NC	6	9.8
EA/HA/APP/NC	1	1.6
EA/EM/FFP/NC	3	4.9
EA/EM/IPE/NC	1	1.6
EA/HA/LPF/NC	4	6.6
EA/EM/LPF/IPE	1	1.6
EA/LPF/IPE/NC	1	1.6
EA/FFA/LPF/NC	1	1.6
EA/FFA/IPE/NC	2	3.3
A/FFA/APP/NC	1	1.6
EA/EM/HA/NC	2	3.3
EA/ES/APP/NC	1	1.6
EA/HA/FIF/NC	1	1.6
EA/HA/LPF/IPE	1	1.6
EA/LPF/APP/NC	1	1.6
EA/FFA/LPF/IPE/NC	1	1.6
EA/EM/HA/APP/NC	1	1.6
EA/EM/HA/IPE/NC	1	1.6
EA/HA/FFA/APP/NC	1	1.6
EA/EM/HA/FFA/NC	2	3.3
EA/Partially compressible	1	1.6
Normal appendices	18	29.5
<b>Total</b>	<b>61</b>	<b>100.0</b>

Abbreviations EA, enlarged appendix >6mm,Em,echogenic mucosa

,HA,hypoechoic appendix LPF,loculated pericecal fluid, FIF, free

intraperitoneal fluid, IPE,increased periappendiceal echogenicity,

APP,appendicolith,NC,non- compressible appendix ,FFA, fluid filled

appendix

Table 7: The Position of the appendix

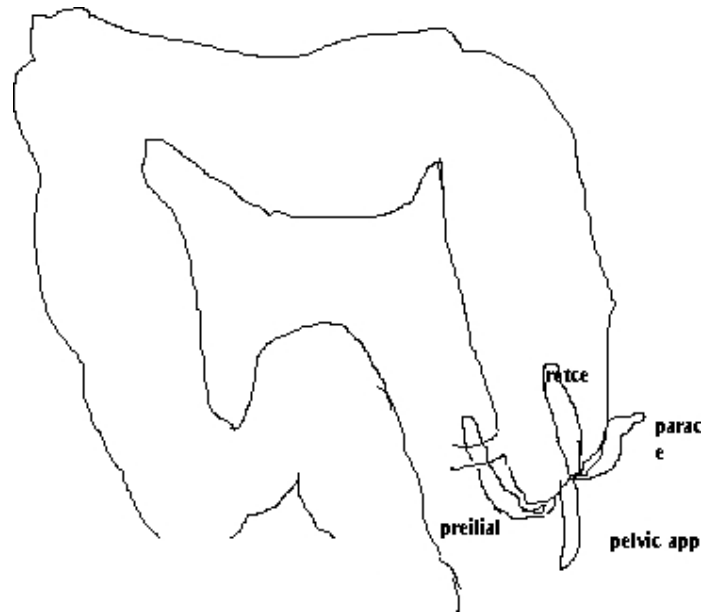
<b>No.</b>	<b>Position</b>	<b>Frequency</b>	<b>Percent</b>
1	Retrocaecal	10	23.3%
2	Paracaecal	5	11.5%
3	Pelvic	5	11.6%
4	Post-ileal	4	9.3%
5	Pre-ileal	2	4.8%
6	Retrocaecal subhepatic	2	4.8%
7	Subcaecal	1	1.6%
8	Undetermined positions	14	32.6%
9	<b>Total</b>	43	100%

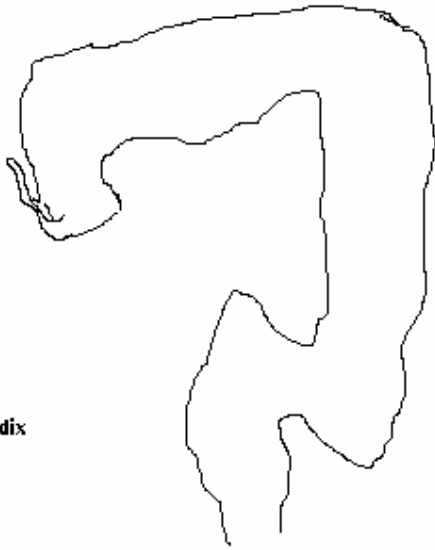Table 8: Cross-tabulation of Position on ultrasound and Operative Findings.

Position	Post operative findings					Total
	Mural	Gangrenous	Perforated	Sealed	App.mass	
Retrocecal	9	1				10
Pelvic	4				1	5
Paracecal	4		1			5
Postileal	4					4
Preileal	2					2
Retrocecal S	2					2
Subcecal	1(1)		(1)	(1)		1
Total	26	1	1		1	29

(3) Subcecal appendices ultrasound has failed to determine the position, two were perforated and one just inflamed .The positions were reported post-operatively.

Malrot figure 1

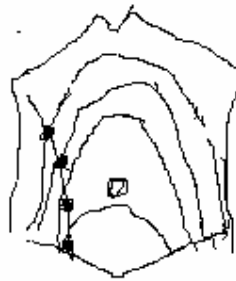



**retrocecal subhepatic appendix**



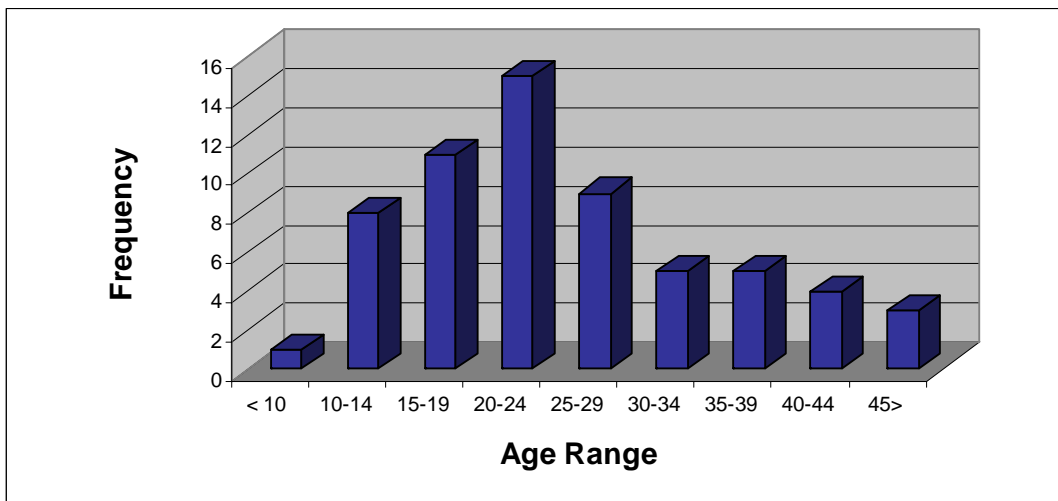
Retroce figure 2

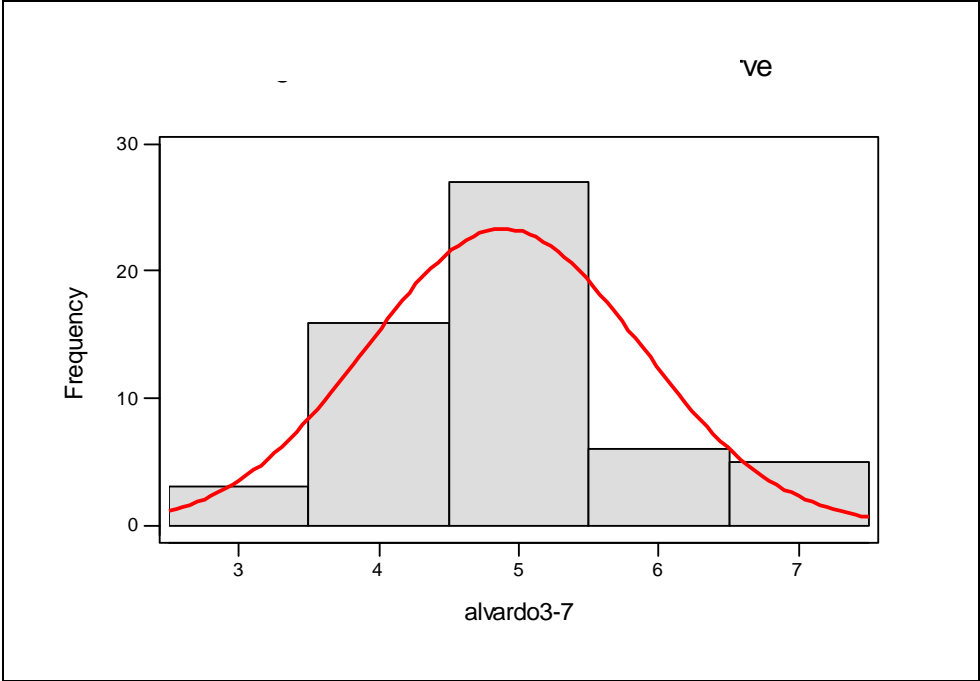


**changing positio of the appendix with pregnancy**

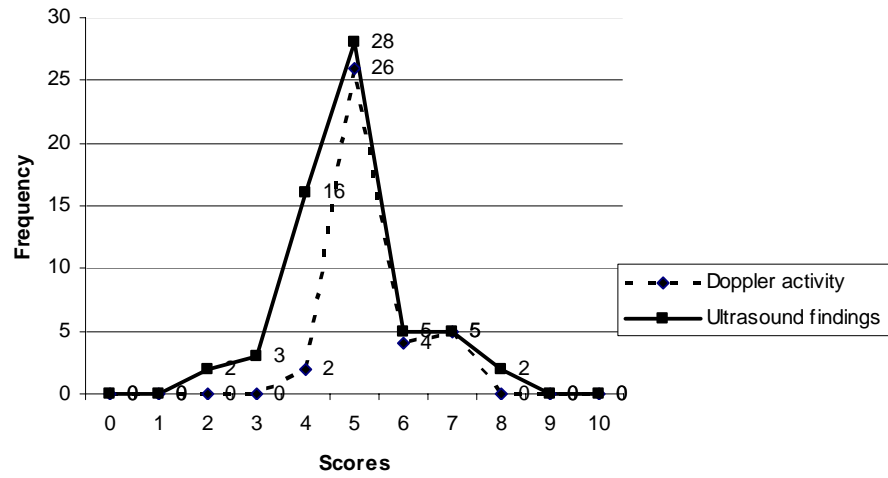
Change pos figure3

**Figure 4 : Frequency of patients suspected appendicitis according to age in years**



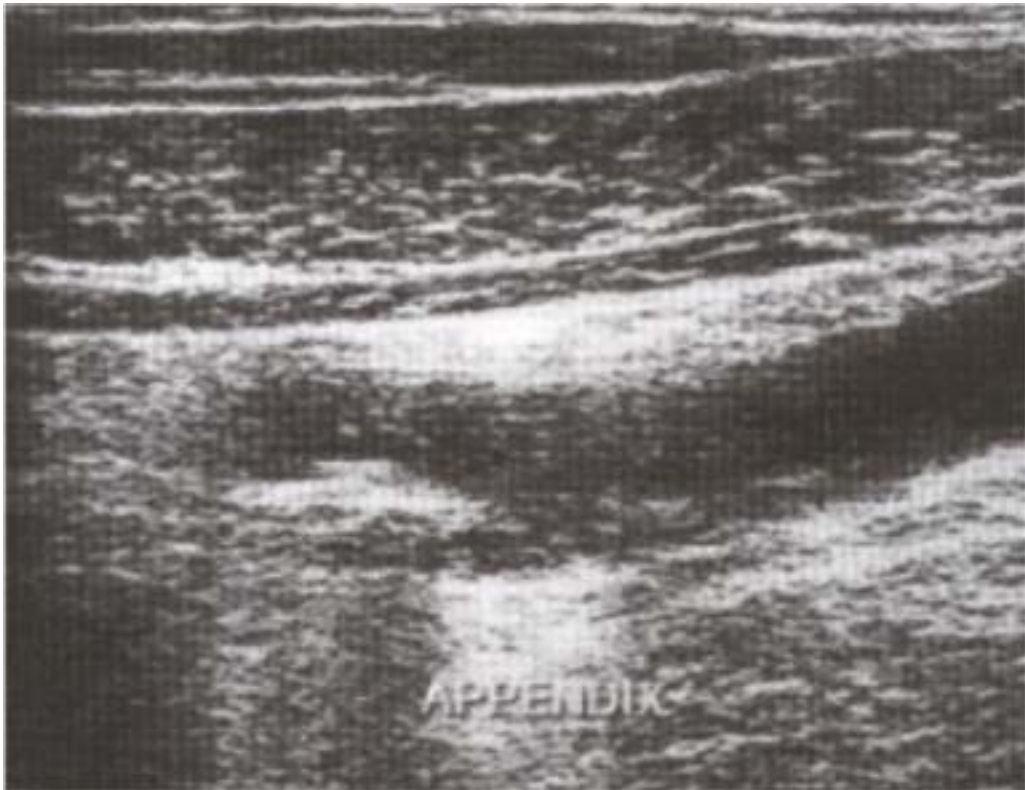

**Figure 5 Showing, Alvarado scores within normal distribution curve**

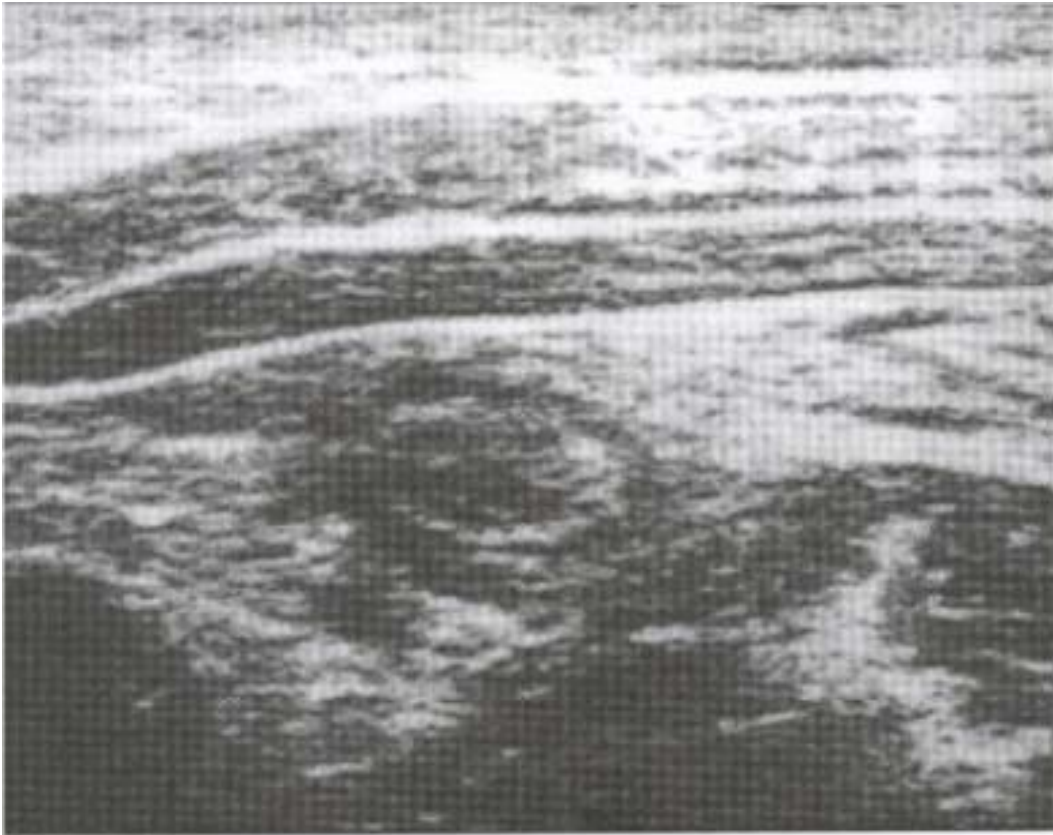

**Figure 6, Matching Alvarado score with ultrasound and Doppler activity**

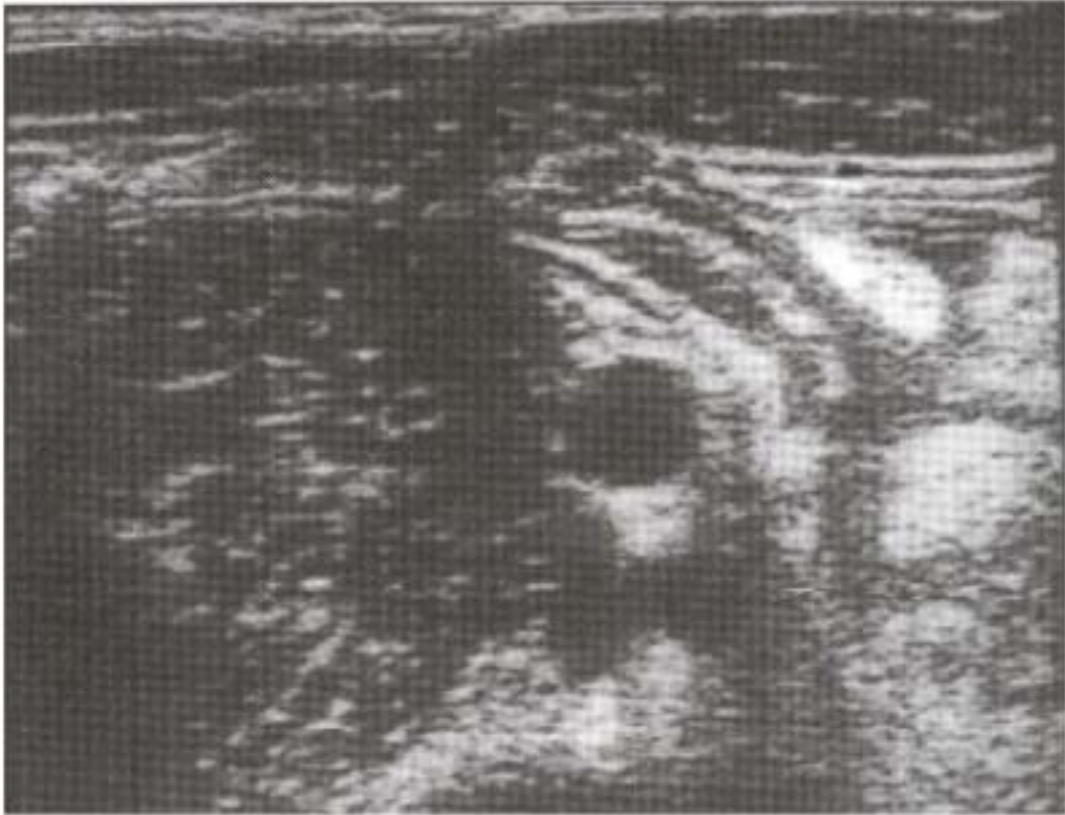



**Fig.8. Enlarged Hypoechoic Appendix With Appendicolith In a Longitudinal Scan.**

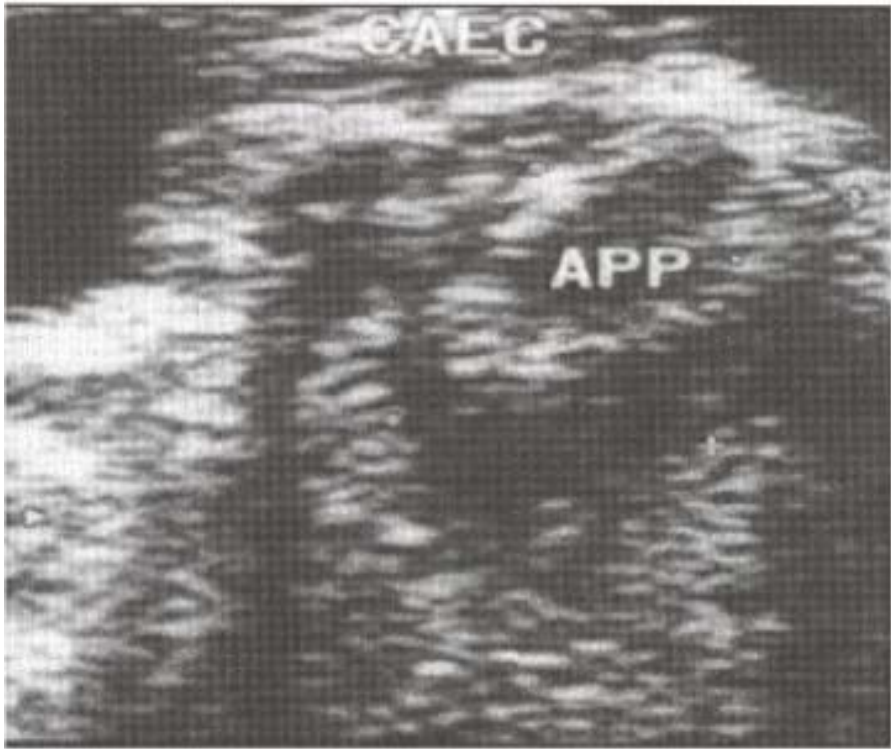


**Fig 9. Inflamed Appendix with Target Sign, In Transverse Scan**

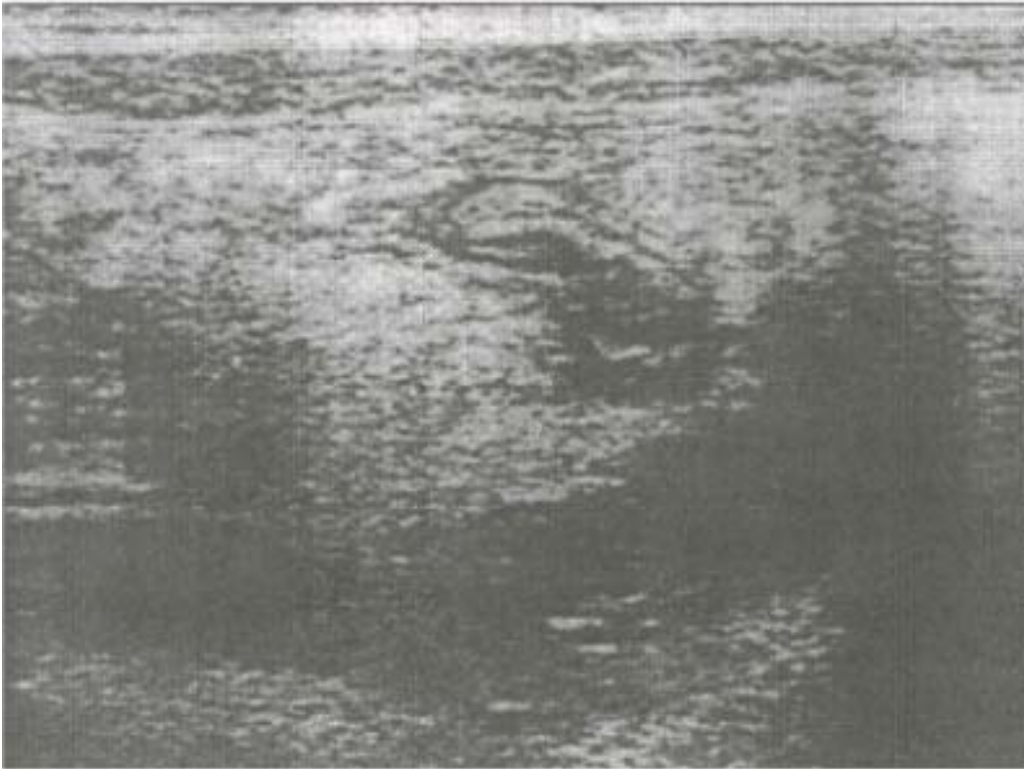


**Fig.10 Enlarged Pelvic Appendix Crossing the Pelvic Brim with Creeping Fat Sign**

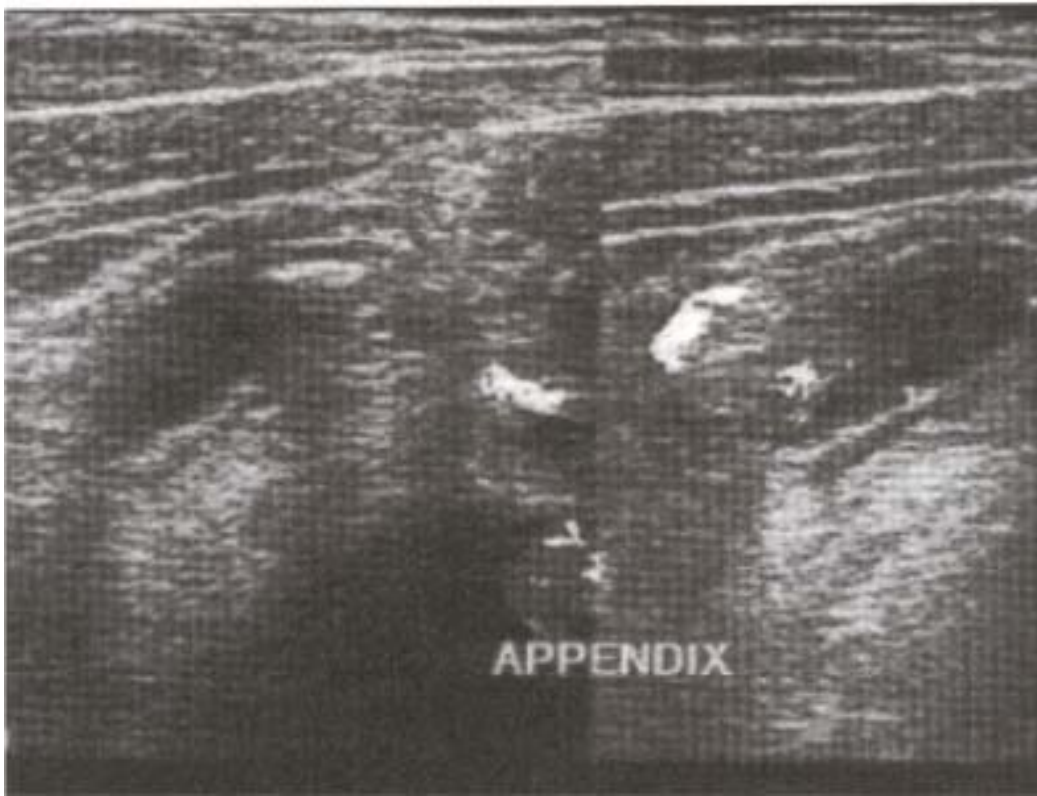




**Fig.11 Enlarged Inflamed Appendix with Periappendiceal Fluid Collection i.e. Sealed Perforation**



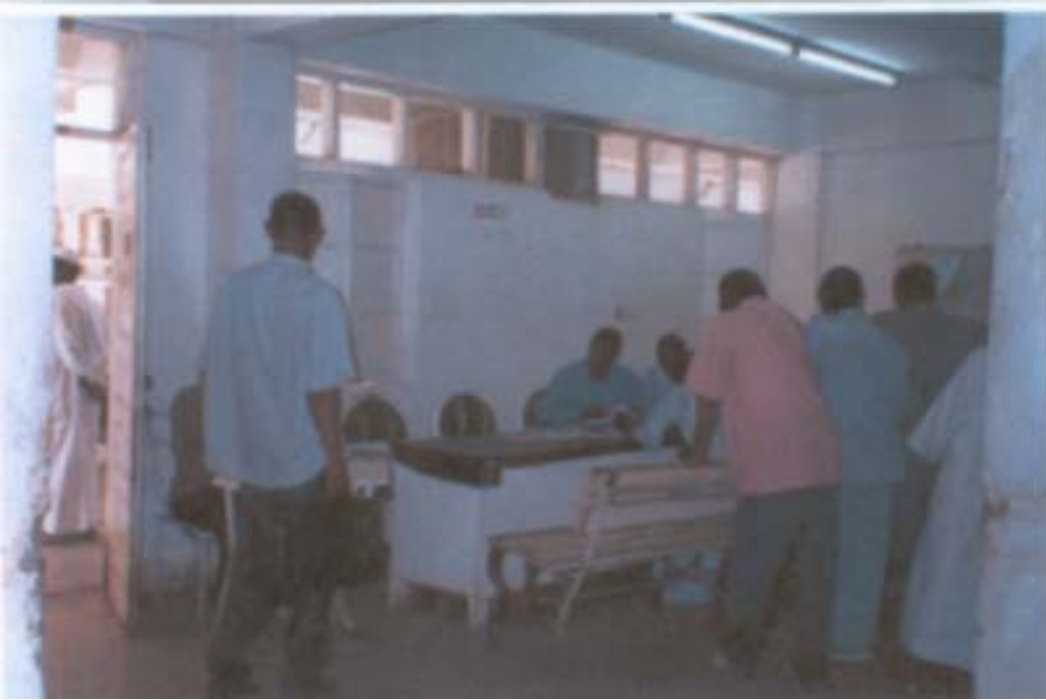**Fig.12. enlarged appendix with breached mucosa and periappendiceal Fluid Collection**



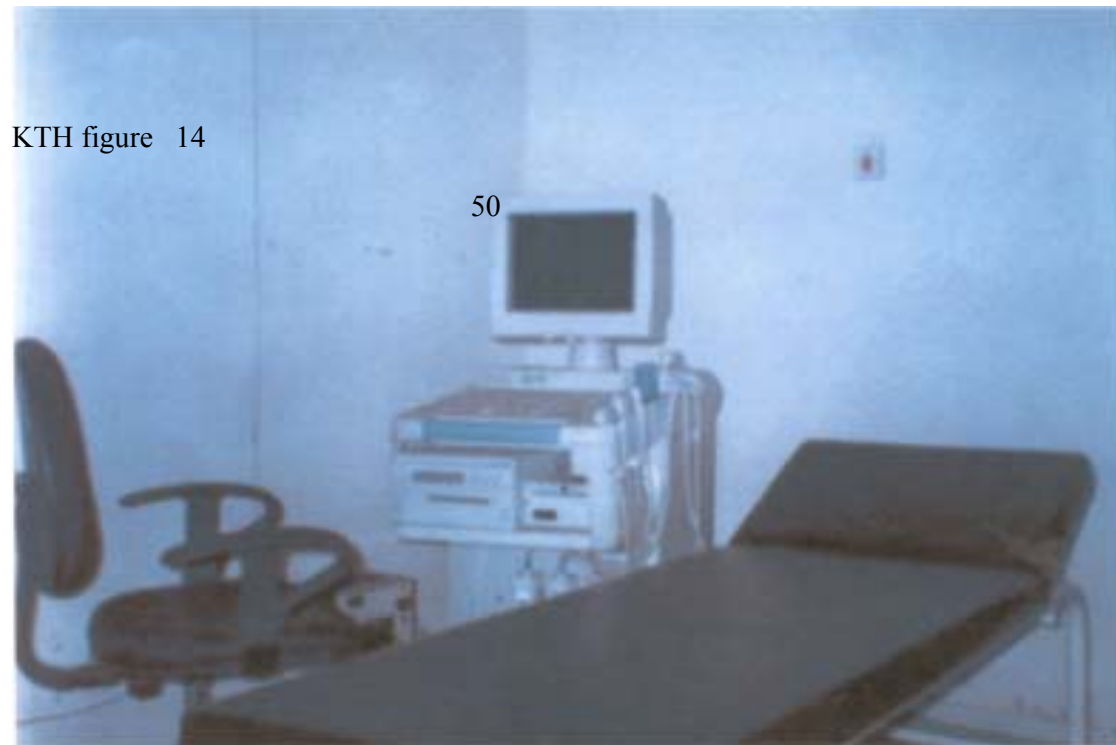
**Fig.13. Inflamed Appendix with Appendicolith in Longitudinal Scan.**



**Fig.14. Khartoum Teaching Hospital Emergency Department**



**Fig .15. The Consultancy Room of the Surgical Department**



**Fig .16. The Scanner Used For the Study**

## **DISCUSSION**

The art of using ultrasound in various disciplines is long dated, in the military is used to detect submarines as well as underground bunkers, and caves in mountains. The American institute of ultrasound in medicine, is the body that governs the use of the use of ultrasound in diagnostic procedures and interventional sonography. This institute convenes annual convention bringing experts from all over the world to share their experience.

It was then found that sonography could be applicable to many medical specialties. The example of detecting aneuploidy of chromosome 21 (Downs syndrome) could be predicted by measuring the fetal nuchal translucency between the 11<sup>th</sup> and 14<sup>th</sup> week of gestation. Four-dimensional sonographic study of fetal heart is able to detect septal defects with colour Doppler. The institute has regional bodies tagged to various regions of the world to promote education and research in the area of sonography. The Sudan belongs to the Middle East domain, the group for the region has already conducted seminars and training seasons in Khartoum. There is further extension of ultrasound use in dermatological conditions as toenail onychomycosis utilizing Doppler. However the bioeffect is continuously being scrutinized, as this one involved the use of high frequency waves, which is accompanied by generation of greater amount of heat, the recommendations of this committee is forwarded to the American institute of ultrasound in medicine.

Clinical examination is the most commonly used method of detecting acute appendicitis in patients presenting at the emergency department as acute abdomen. However sonographic evaluation of acute appendicitis is increasingly gaining

ground as a new imaging modality. The first report of sonographic demonstration of an inflamed appendix was in 1981. The report that, the use of graded compression sonographic technique helps to diagnose acute appendicitis, has validated the high sensitivity and specificity of sonography.<sup>28</sup> The enlarged hypoechoic appendix means that, the continuously increasing intraluminal mucous secretion is sufficient enough to cause distention and enlargement of the acutely inflamed appendix. An enlarged appendix has the cut-off limit of 6mm or more (i.e the outer diameter of the appendix), values greater than this are considered to be a sign of acute appendicitis. All the diagnosed conditions of acute appendicitis have enlarged diameter greater than 6 mm and the peak was 13mm. See figure 7 (page 44). A study to evaluate the usefulness of and the limitation of this criterion found that it confirms acute appendicitis and provides high sensitivity, but limited specificity, the cut-off limit of 7mm has higher accuracy rate than 6mm, but may cause appendicitis to be overlooked.<sup>29</sup> Evaluation of maximum mural thickness (MMT) of the appendix in asymptomatic pediatric population suggests that, children aged 6years or younger the appendiceal mural thickness is normal only when less than 3mm.<sup>30</sup>

The enlarged appendix with loculated periappendiceal /pericecal fluid means, the inflammation has extended through the wall causing fibrino-purulent reaction over the serosa, but no perforation, this was the condition in four patients. The enlarged inflamed appendices with intact echogenic mucosa, indicating that no ulceration or foci of necrosis, and there was no intramural gas seen. A study conducted for the



presence of intramural gas in acute appendicitis using control group and patients suspected of acute appendicitis with pain in the right iliac fossa. The percentage of gas containing inflamed appendices were lower with gangrenous appendicitis than with moderately inflamed (catarrhal, erosive or ulcerative appendicitis), it was then concluded the presence of gas is more reliable sign to exclude appendicitis, whereas the absence of gas helps to confirm acute appendicitis.<sup>31</sup>

The presence of appendicolith in most of cases is the cause of obstruction, this is identified as a highly echogenic focus casting posterior shadow. See figure 8 (page 45), and subsequent figures 9-13 show various inflammatory stages of the appendix. The enlarged appendices with increased periappendiceal echogenicity, is due to migration of the greater omentum to arrest the inflammation of the appendix. This has the characteristic of increased echogenicity (creeping fat sign), this mechanism is lacking in children hence they can develop general peritonitis. The sonographic feature of free intraperitoneal or periappendiceal fluid collection with breached mucosa means that there is a perforation, and such patients usually have reported late to the hospital. There was a false negative ultrasound finding in a child of seven years. It was only proved postoperatively as the clinical presentation was rather vague. It is recommended that abdominal ultrasound to be performed on any child with doubtful clinical diagnosis of acute appendicitis helping the surgeon to take decision to perform laparotomy.<sup>32</sup> This was evident in a case report of sonographic finding of acute appendicitis in nine month old child with well-established sonographic criteria for the disease, and the

size of the appendix was the same as for adult. Perforation was a major complication of the disease related morbidity. This is associated with delay in treatment in younger age.<sup>33</sup>

The study was reasonably able to differentiate between appendicitis and acute gynecological pathology. There was a patient who had acute pelvic inflammatory disease with fluid collection in cul-de-sac, and another patient with retrocecal appendix plus right ovarian cyst. The clinical misdiagnosis of appendicitis is highest in adult women aged 20-40 years, and sonography excels in imaging pelvic pathology. The normal appendix was seen as a collapsed, thin wall structure (3mm) in ten out of the eighteen negative scans and there was no Doppler activity. This is comparable to new figures of 60-85% of normal appendices seen on routine scan.

Alvarado scores at the extremes, three and downhill are suggestive for conservative management, scores of seven and above is for surgical management. The range of scores 4, 5, 6 should undergo imaging, as they lie within the grey area, and possible benefit include decrease in negative operations. Alvarado score is safer, faster and more accurate than graded compression ultrasonography alone, but fails to produce better outcome than unaided clinical diagnosis.<sup>34</sup>

The result of Doppler showed increased Doppler activity in eighty six percent of patients with acute appendicitis, and the activity centered on patients with Alvarado score of 5, so patients that fall in the middle of Alvarado scores, with equivocal clinical presentation, Doppler ultrasound adds more information as

hyperemia due to inflammation can be seen by this method. The calculated accuracy for Doppler was 70.5%. In patients where no Doppler activity detected could be due to technical failure in adjusting the set.

In matching the ultrasound, Doppler and Alvarado scores, ultrasound and Doppler findings run in two parallel lines, with Doppler frequencies within the ultrasound frequencies. This means there is a close correlation between the two modalities, and Doppler signals depend on inflamed appendices. Sonography and Doppler are useful adjuncts when clinical findings are inconclusive (scores 4, 5, 6) and possible benefit includes decrease percentage of negative operations.

The use of graded compression technique has been precise and adequate, yielding reliable results even in small sample size.

Four patients had plain films of abdomen and chest for their vague symptoms and signs, all showed no abnormalities, despite good quality films. Plain films are unnecessary as a normal X-ray films did not exclude serious pathology as acute appendicitis, sonography may provide more useful information. The report on the films are neither sensitive nor specific, and frequently misleading, they are costly and should not be routinely obtained on suspicion of acute appendicitis.<sup>35</sup>

None of the patients had CT despite its accuracy; the same was true for MRI despite its superiority. Comparison between ultrasound and CT finding in negative appendectomies and perforation rates in children, it was found that children who underwent no pre-operative imaging were compared with those who underwent ultrasound and those who underwent CT for clinical suspicion of appendicitis. The

imaged children had significantly lower rates negative appendectomies and lower rates of perforated appendicitis. The perforation rates were not significantly different in the three groups.<sup>36</sup>

The study has elucidated almost all sonographic finding in acute appendicitis, confirms that, the threshold of 6mm diameter of the appendix under graded compression is accurate and gave the sensitivity of 97%and specificity of 100%.

On evaluation of sensitivity, specificity and the predictive values of ultrasound, Doppler and laparotomy findings the appendix was identified in 86% of the patients, which included 96% of patients with and 72% of patients without appendicitis.<sup>37</sup> Cross-tabulation of position of the appendix on ultrasound and postoperative findings, in ninety percent of conditions of inflamed appendix the positions have been sonographically determined. This by it self is a significant contribution of ultrasound in locating the exact position of inflamed appendix, so radiologist performing sonography for appendicitis, should report on the position to help in the surgical approach. This may not be real in the nearest future as scanners of high frequency are still limited in number, and skill promotions needed.

The majority of patients, who experienced primary epigasric /umbilical pain with nausea and vomiting, constitute about seventy percent comparable to figures in literature. The history of migratory pain in relation to its anatomical site and the direction of shift plus leucocytosis above 1500,<sup>-3</sup> and sonographic appearance had the highest positive predictive value, and sonography is most useful in intermediate

probability of the disease, and should be avoided in patients with high and low likelihood of the disease. The evaluation and the treatment of acute appendicitis remain unchanged for the majority of the individuals who present with the disease. Despite the imaging advancement, it has not replaced the clinical evaluation. Imaging is being a useful adjunct in atypical presentation, especially in more focused groups of young and old. This led to improved outcomes and decreased overall cost. Early diagnosis of appendicitis is associated with low morbidity and mortality.<sup>38</sup>

## **CONCLUSION**

This study has expressed a Sudanese experience in sonographic imaging of acute appendicitis. It has confirmed the usefulness of ultrasound as an additional diagnostic tool in appendicitis with high confidence.

Keen scanning plus graded compression and Doppler ultrasound imaging is valuable adjunct tools in locating the position of the appendicitis, and for decision making in equivocal clinical presentation.

## **RECOMMENDATIONS**

1. A larger study of sonographic imaging of acute pelvic conditions with special emphasis on females of reproductive age
2. Ultrasound imaging in acute appendicitis should be for equivocal cases mostly
3. Doctors should be educated on how to interpret the sonographic image of acute appendicitis, and its complications
4. New scanners with high frequency probes and better resolution should be purchased for accident and emergency Departments in the Sudan, and duty radiologist made available.
5. Short courses of CME for doctors to cope with the rapidly developing field of sonography with emergence of 3D scanners

## **REFERENCES**

1. Bisset, R Khan A N Differential Diagnosis in Abdominal Ultrasound 2<sup>nd</sup> edition. W.B Saunder; 2002 page 277-278
2. Schwartz, Shires Spencer. Principles of Surgery 7<sup>th</sup> edition. New York:McGram-Hill Book Company ; 1999 page 1383-1393
3. Persau, K M Developing Human Clinically Oriented Embryology 6th Edition W B Saunder Comp 1998 page 290
4. Gary, F Cunningham's. Norman, F G Williams Obstetrics 21st edition Mc GrawHill 2001 page 1281-1282
5. Gilani, Syed Amir Abdominal and Retroperitoneal US Maha Publishing Company 2003 page 25-31
6. Chen, S.C Lin, F-Y Accuracy of sonography in diagnosis of peritonitis , compared with the clinical impression of surgeon. Arch surgery 2000; 135:175-173
7. Lane, M J Unenhanced CT for suspected acute appendicitis American Journal Roentgenology 1997Feb 168(2);405-9,
8. Rao, PM Feltmate CM,Rhea JT .et al Helical computed tomography in differentiating appendicitis and acute gynecological condition Obstetrics and Gynecology 1999 March 93(3):417-2,
9. Rao, PM Rhea, P et al Helical CT technique for Diagnosis of Appendicitis Evaluation of A Focused Appendicitis CT Radiology1997Jan 202(1): 139-44;



10. Dalrymple, N C. Verga, M et al The Value of Unenhanced CT in Management of Acute Flank Pain Journal of urology 1998 Mar 159 (3); 735-40
11. Incesu, L. Coskun, A. Selcuk, M B. Akan, H Acute Appendicitis: MR Imaging and Sonographic Correlation American Journal of Roentgenology 1997 Mar 168 (3); 669-674
12. Sabra, J. Roh, M. Paez, X Use of sonography in diagnosing acute appendicitis: Comparison of teaching hospital and community hospital Academic Radiology, 1996 May 3(5); 438-41
13. Bathazar, E J. Birnbaum, B A et al Acute Appendicitis CT and Ultrasound Correlation in 100 patients Radiology 1994;190:31-35
14. Walsh, P F. Crawford, D et al The value of Immediate Ultrasound in Acute Abdominal Condition, critical appraisal. Clinical Radiology 1990 July 42(1); 47-49
15. Schwerk, W B Acute and Perforated Appendicitis: Current experience With Ultrasound Aided Diagnosis World Journal of Surgery 1990 Mar-Apr 14(2): 271-6
16. Sim, K Picores, T. Grade, M. Sweeny, J P ultrasound graded compression evaluation Journ. of National. Medical Association 1989 Sept 81 (9) 954-957
17. Kim, KT et al Appendicitis: Usefulness of color Doppler Us. Radiology 1996 201:221-225

18. Fa, E M. Cronan, J J Compression Ultrasonography as an Aid in the differential diagnosis of acute appendicitis. *Surgery, gynecology and obst*, 1989 Oct. 169 (4); 290-8
19. Amland, P F. Skaone, P. Ultrasonography and Parameters of Inflammation in Acute Appendicitis--A Comparison With Clinical Finding. *Chirurgica Scandin* 1989 Mar 155(3); 185-189
20. Risser, W L. Pokorny, S F. Ultrasound Examination of Adolescent Females with Lower Abdominal Pain. *Journal of adolescent Health care* 1999 Sept 9(5): 407-410
21. Asreggiano, M. Bresso, F. et al Abdominal Pain and Bowel Dysfunction: Diagnostic role of intestinal ultrasound. *Euro. Jour of Gastro hepatology* 2001 Aug + Ads 13 (8): 927-931
22. Stephen, PL. Mazzucco, J J comparison of ultrasound and Alvarado Score for Diagnosis of Acute Appendicitis. *Conn. Med.* 1999 Mar 63(3); 137-140
23. Saidi, H S. Chavda, SK Use of Modified Alvarado score in Diagnosis of acute Appendicitis. *East Africa Medical Journ.* 2002 Aug; 80(8): 411-14
24. Teicher, I Landa, O R et al Scoring System in the Diagnosis of Acute Appendicitis *Ann Surgery* 1983; 756-759
25. Bhattacharjee, P K. Chowdhury, J Roy D Prospective Evaluation of Modified Alvarado Score for The Diagnosis of Acute Appendicitis *Journal of Indian Medical. Asso.* 2002; May 100 (5); 310-314,

26. Pruek, P Prasert Accuracy In Diagnosis of Acute Appendicitis By Comparing C-reactive Protein Measurement ,Alvarado Score and Clinical Impression Radiology 1986 Feb 158 (2): 335-360
27. Bendeck, S E. Nino-Murica, M Berry, G Jeffery, R B J r Imaging of suspected appendicitis: Negative appendectomy and perforation rate. Radiology 2002 Oct 225(1): 131-6
28. Puyiaert, JB, Acute Appendicitis :US Evaluation using Graded Compression Radiology 1986 Feb 158( 2):335-360
29. Simonovsky, V MD Csc Normal Appendix: Is There Any Significant Difference in Maximum Mural Thickness at Ultrasound Between Pediatric and Adult Population? Radiology 2002 224:333-337
30. Rettenbach, T MD, Hollerweger, A et al Study of Presence of Gas in the Appendix, Additional Criterion Radiology 2000 Jan 214(1): 183-187;
31. L, Cere Alonso, I Lopez Ultrasound Study of Acute Appendicitis in A Child With Emphasis Upon the Diagnosis of Retrocecal Appendix Pediatric Radiology 1999; 20(4): 258-61
32. Cherniavsky, E MD, et al A case report Acute Appendicitis in Nine Months Infant Journal of Ultrasound in Medicine 2004 23 (6): 865-8
33. Charles, D. Douglas, C et al Randomized Controlled Trial of sonography in Diagnosis of Acute Appendicitis, in incorporating Alvarado Score Br. M J ; 2000 321: 1-7.

34. Vertmeulen, B .MD. Morabia, A et al Acute Appendicitis :Influence of Early Pain Relief On the Accuracy of Clinical and Ultrasound Findings in Decision to Operate – A Randomized Trial Radiology 1999;210:639-643;
35. Anyanwu, A. Moalypour, C Are Abdominal Radiography Still Over Utilized in Assessment of Acute Abdominal Pain? J Roy. Colleg. Ed; 1998; 43: 267-270
36. Kimberly, E. Applegate, A, MD, et al Effect of Cross-sectional Imaging on Negative Appendectomy and Perforation Rates in Children. Radiology; 2001; 220:103-107
37. Kessler, N MD, Cathrine, C et al Appendicitis: Evaluation of Sensitivity, Specificity and Predictive Values of Ultrasound, Doppler Ultrasound and Laboratory Findings Radiology 2004; 230:472-478
38. Wilcox, RT Traverso, L W Have the Evaluation and Treatment of Acute Appendicitis Changed With New Technology? Surgical Clinic of North America 1997 Dec; 77(6): 1335-70;

